



orthomed

·SOP TPLO User Guide·

An IVOA development



## Introduction

Locking plate technology has become increasingly popular over the last decade in both medical and veterinary orthopaedics. There are many valid reasons why this is so, however until the advent of the SOP plating system all other locking plates utilise dedicated locking screws to achieve angular stability between the screw and the plate

The original SOP plating system combines a novel plate which allows contouring and twisting in six degrees of freedom, the technology within the plate design takes a regular cortical bone screw and locks it. The careful development of the plate to use a standard screw when used in conjunction with the SOP User Guide created a successful locking plate system designed by veterinary surgeons for veterinary surgeons.

### **The SOP TPLO plate is the natural evolution of the technology and provides the following benefits over traditional plates:-**

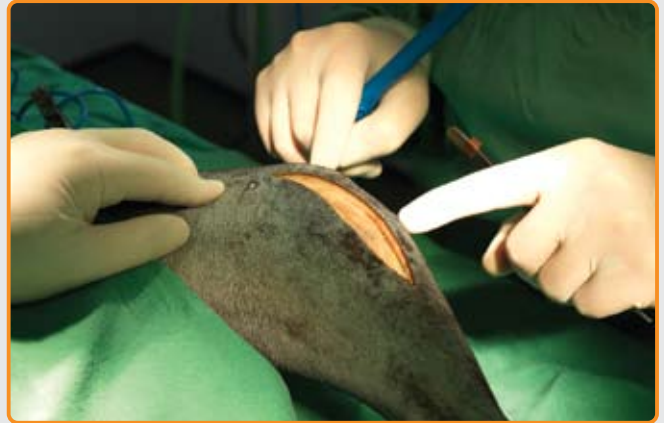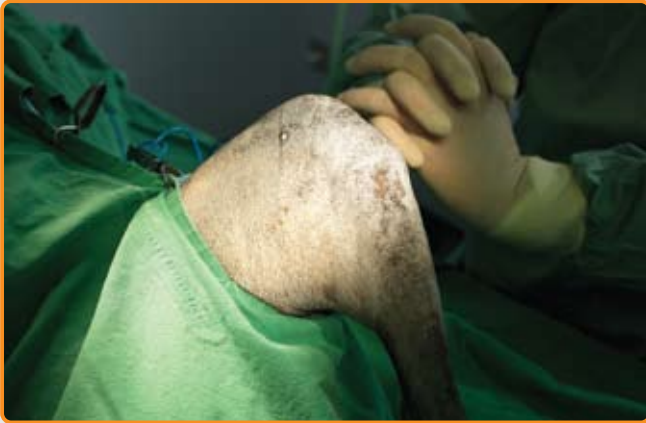- SOP TPLO is a locking implant and addresses concerns of impaired vascularity beneath bone plates
- Angular stability of the locked screws is substantially more resistant to pull out, so the risk of catastrophic implant failure will be reduced
- SOP TPLO is stiff and this combined with the angular stability afforded by the locked screws will minimise the risk of post-fixation subsidence of the proximal tibial fragment
- SOP TPLO is symmetrical – there is no longer a need for different left and right plates; this coupled to the fact that it uses regular screws means reduced implant costs
- The 3.5mm SOP TPLO plate is designed to be used with 18mm, 24mm and 30mm osteotomy saws and is therefore appropriate for use in a wide range of patients from approximately 15kgs upwards. For larger patients (approximately 35Kgs upwards) the SOP TPLO plate is supplemented with a standard 4 or 5 hole 3.5mm SOP plate

### **The SOP TPLO system differs somewhat from conventional TPLO plates and we have listed some of the frequently asked questions:-**

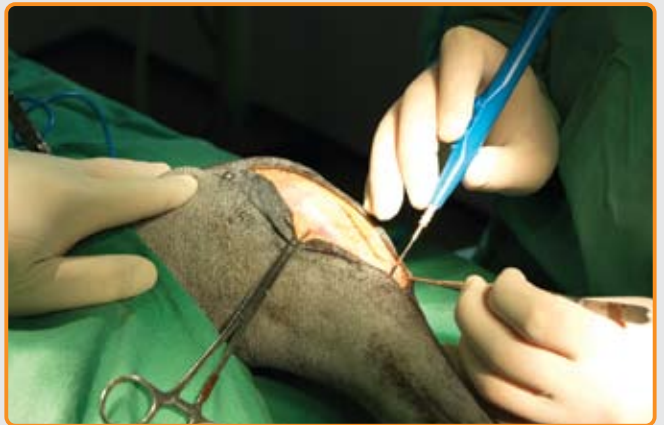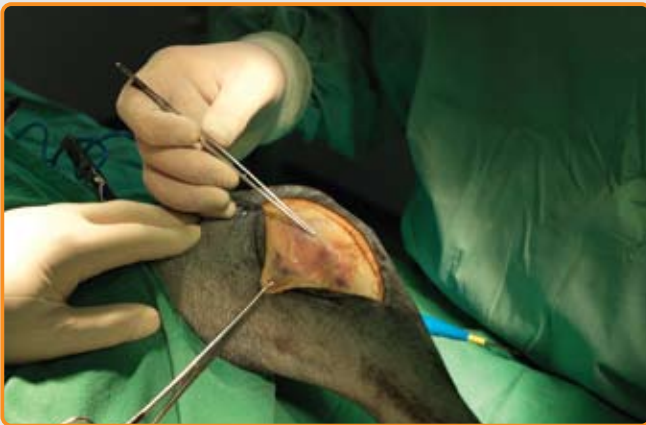- “The plate looks bulky.” – Certainly the plate is thicker than some TPLO plates, however the initial experience, including one dog of 12.5Kgs has revealed no problems associated with soft tissue closure over the plate or prominence of the implant after surgery.
- “There is no facility for compression.” – Locking plates act invariably as buttress implants so there is never any potential for dynamic compression with a locked plate system. The curved osteotomy is inherently very stable and the use of pointed reduction forceps as shown in this user guide ensures that an excellent and accurate reduction is achieved and maintained whilst the plate is applied.
- “The plate can’t be contoured.” – Accurate contouring of locking plates is not necessary and it is of no consequence if part (or all) of the plate is “stood off” the bone by a millimetre or two.
- “The proximal screws can’t be directed away from the stifle joint.” – The plate has been designed to avoid inadvertent breach of the stifle joint, even in relatively small dogs. An inherent part of the TPLO procedure is the making of an osteotomy in a suitable position on the tibia and perpendicular to the long sagittal axis of the bone. The osteotomy acts as a datum for placing the plate. The length of the plate applied to the medial axis of the tibia ensures that the screw cannot be directed “too high” and the positioning of the laser marked dot directly over the osteotomy avoids inadvertent proximal translocation of the plate.
- “The caudal, proximal screw invades the proximal fossa of the tibia and might hit the popliteal artery.” – With soft tissues properly retracted – either as shown in this guide, or conventionally using surgical sponges – the exit of this drill/screw is visible so injury to the popliteal artery or any other caudal stifle structures will only occur following fairly substantial surgeon error.

# SOP TPLO

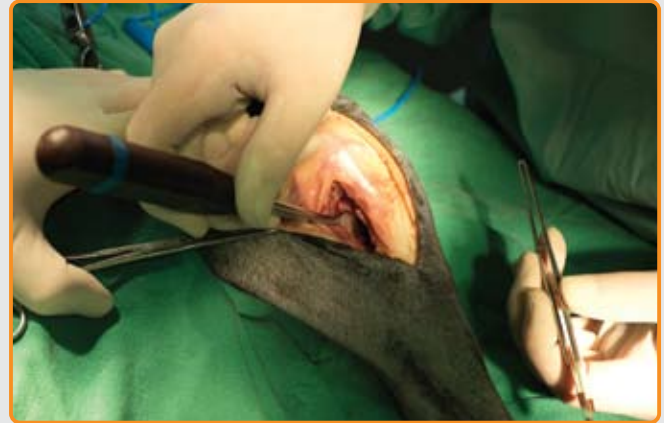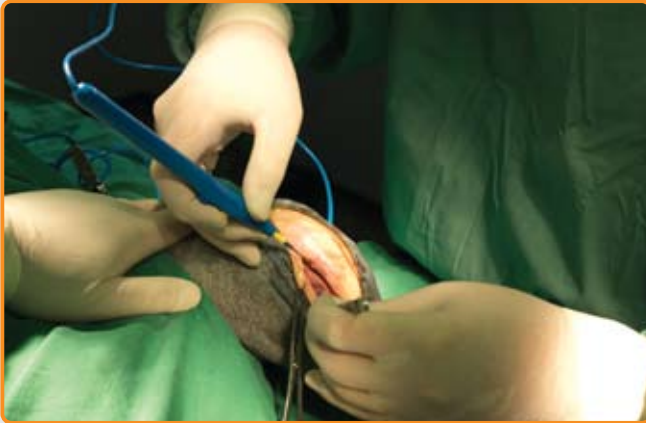## User Guide



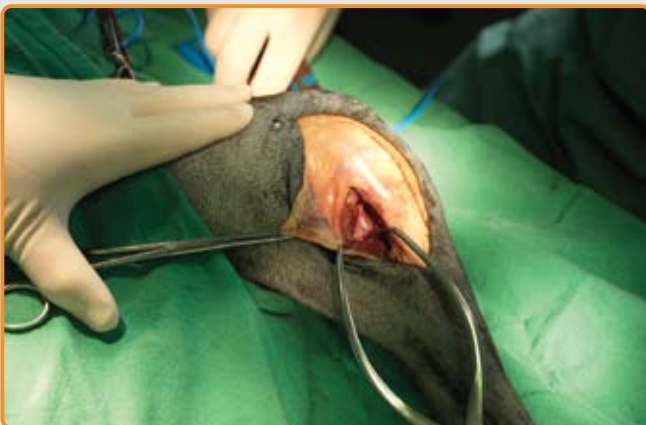- 1 The patient is positioned in dorsal recumbency and draped such that the foot is free and the surgeon has access to all aspects of the limb between the distal femur and the hock.
- 2 Using cutting diathermy, an incision is made on the cranio-medial aspect of the limb starting proximally at the level of the proximal pole of the patella and extending distally to the end of the tibia crest.



- 3 With the skin edges reflected, the incision is deepened - proximally, a medial parapatellar incision approximately 2mm medial to the edge of the straight patella ligament. The incision is made only into the infra-patellar fat pad - there is no need to penetrate the joint unless inspection of intra-articular structures is required.
- 4 The same incision is extended distally down to the bone and along the length of the tibial crest.



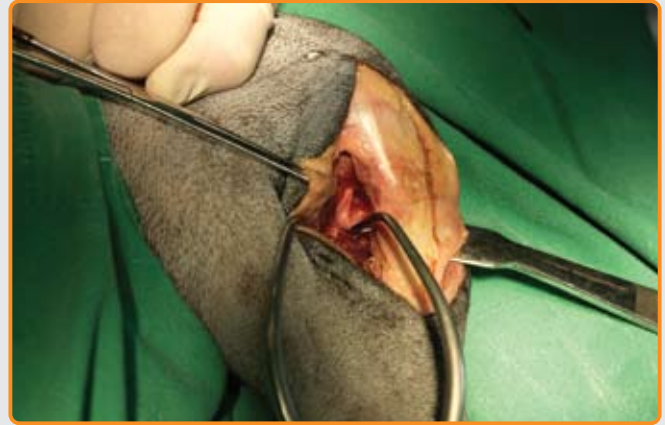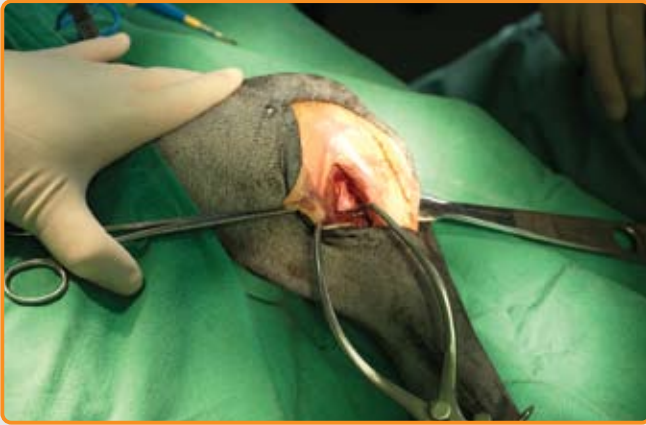- 5** The thick, deep fascia including the so-called pes anserinus tendon is identified and undermined to expose the medial aspect of the tibia and the medial collateral ligament. The standard meniscal release technique can be performed at this point if required.
- 6** An incision is made along the caudo-medial edge of the tibia to allow periosteal elevation of the muscles from the caudal aspect of the proximal tibia. Great care is taken to stay very close to the bone to avoid damaging adjacent vessels and nerves.



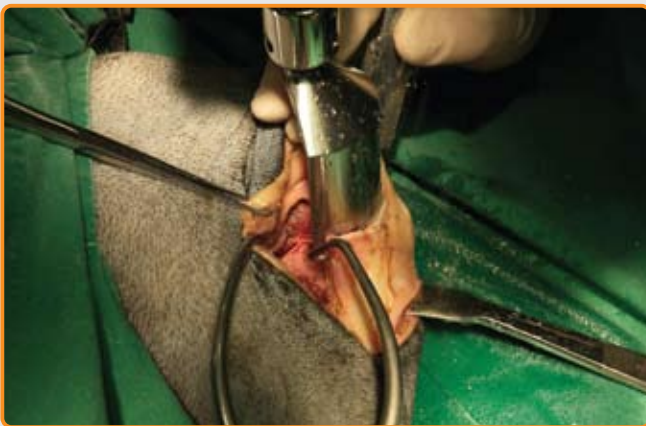
- 7** Gelpi self retaining retractors are placed to hold the recently elevated soft tissues away from the bone. A second incision is made along the cranio-lateral aspect of the tibial crest and a periosteal elevator is used to expose this same cranio-lateral aspect of the proximal tibia.

The original TPLO technique describes the use of surgical swabs/sponges to maintain soft tissue retraction. However, Farrell et al 2009, reported a neat in vitro study which demonstrated significant cotton debris is produced by the action of the osteotomy saw - this is a potential source of foreign body reaction/infection. The same author found that iatrogenic saw damage of soft tissues was relatively limited and the technique here described was derived from the findings of Farrel's research (Ex vivo evaluation of the effect of tibial plateau osteotomy on the proximal tibial soft tissue envelope with and without the use of protective gauze sponges, Vet Surg 38 issue 5:636-644, 2009).

# SOP TPLO User Guide



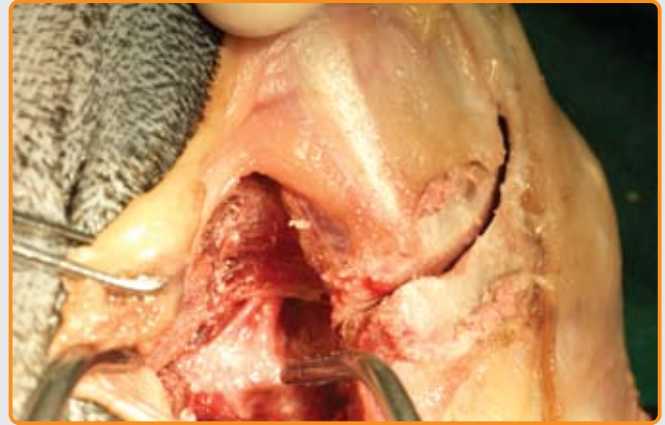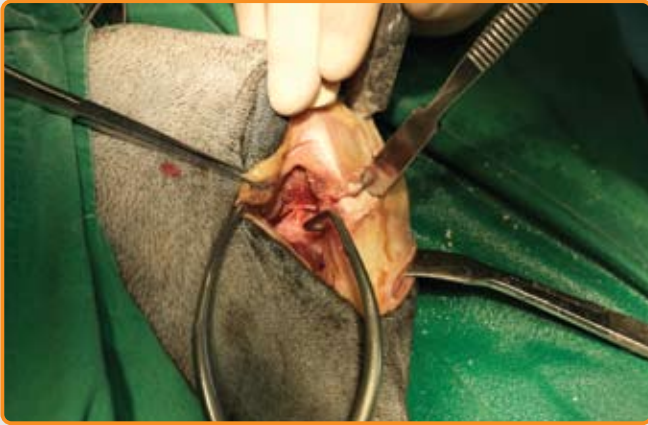- 8 Retraction of the cranial tibial muscle is maintained by placing a Hohmann retractor as shown.
- 9 The proximity of the caudal neurovascular structures as well as the efficacy of this method of retraction is evident.



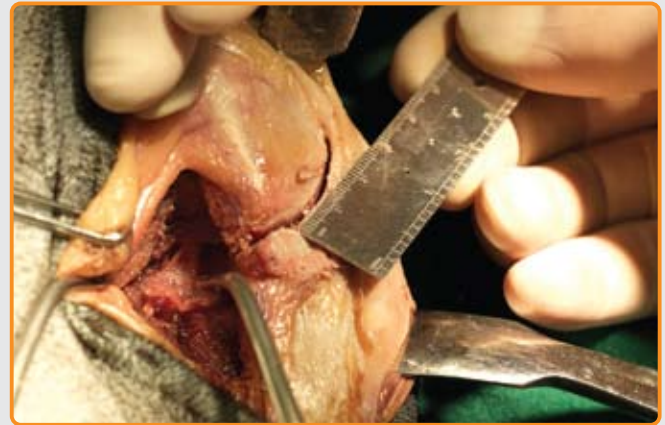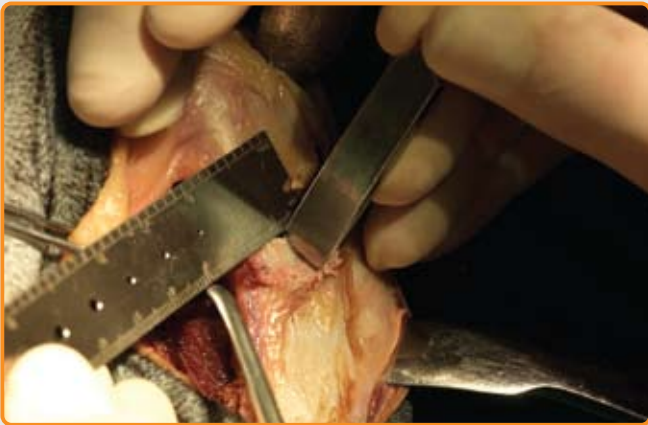- 10 The limb is laid flat on the operating table with the stifle and hock held in 90 degrees of flexion to replicate the position used to collect the pre-surgical measuring radiograph. With the oscillating saw held perpendicular to the table (and therefore perpendicular to the sagittal plane of the limb) the osteotomy is started.

Several publications have reported the effect varying the position of the osteotomy. Original advice that an appropriately sized saw blade should "exit" the caudal cortex at 90 degrees is a good "rule of thumb" but for best results, surgeons should strive to place the centre of the saw blade above the centre of the rotation of the stifle joint, Kowaleski et al. The effect of Tibial Plateau Levelling Osteotomy position on cranial tibial subluxation an in vitro study, Vet Surg 34 issue 4, 332-336, 2005.

(The original Slocum TPLO technique employed a cutting jig but Bell and Ness, Does use of a jig influence the precision of tibial plateau levelling osteotomy surgery, Vet Surg 36 issue 3: 228-233, 2007, demonstrated that the use of a jig did not improve the accuracy or precision of routine TPLO surgery).

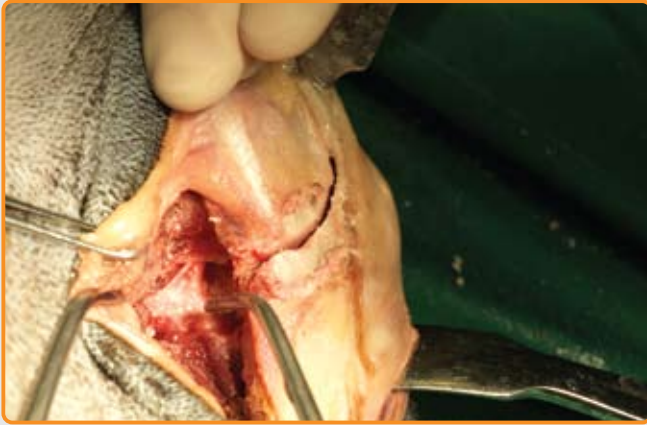

- 11** Before breaching the trans cortex, the osteotomy is suspended. Minimal periosteal elevation is used to expose an area of bone and an osteotome is used to make a shallow mark across the curved osteotomy.
- 12** Close up of the marks made across the osteotomy.

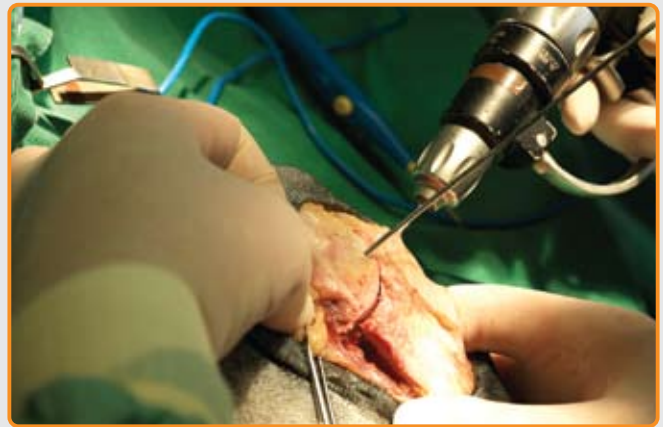
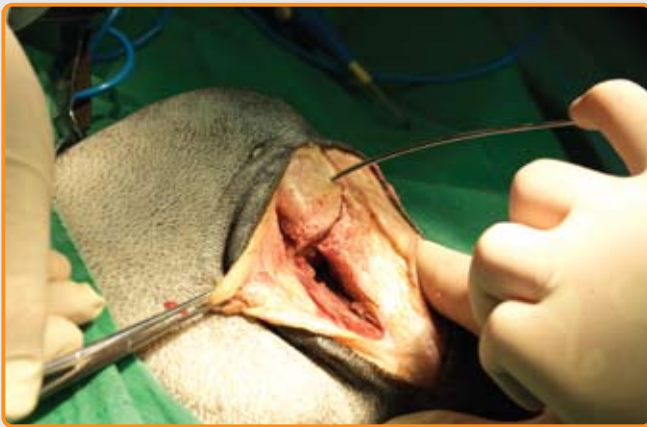
- 13** Using a ruler and the measurement from the pre-surgical planning radiographs, a second mark is made using an osteotome.
- 14** The mark is measured again to ensure that no error or inaccuracy has appeared.

# SOP TPLO User Guide

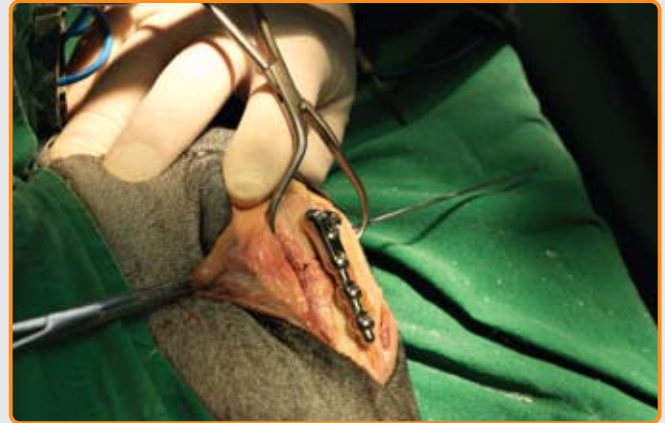
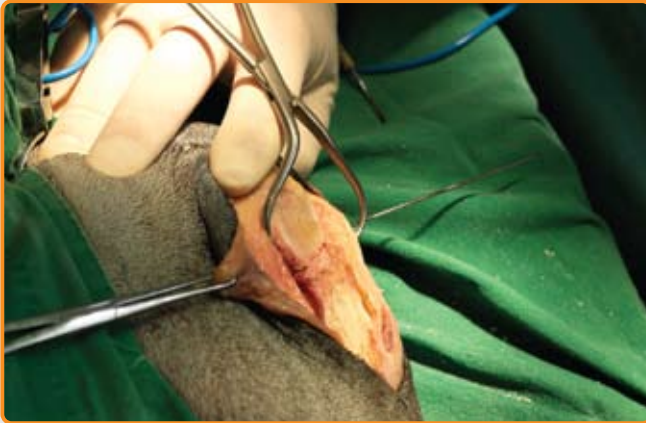
- 15** Using the oscillating saw, the osteotomy is completed - the proximal tibial fragment can be seen to be free. A stout arthrodesis wire is driven deep into the proximal fragment taking care not to penetrate the trans cortex.



- 16** The arthrodesis wire is used as a "handle" to rotate the proximal tibial fragment until the measuring marks are aligned indicating that the tibial plateau has been levelled.
- 17** A second, much smaller, arthrodesis wire is driven through the most proximal part of the tibial crest and into the proximal tibial fragment to maintain rotation and reduction.

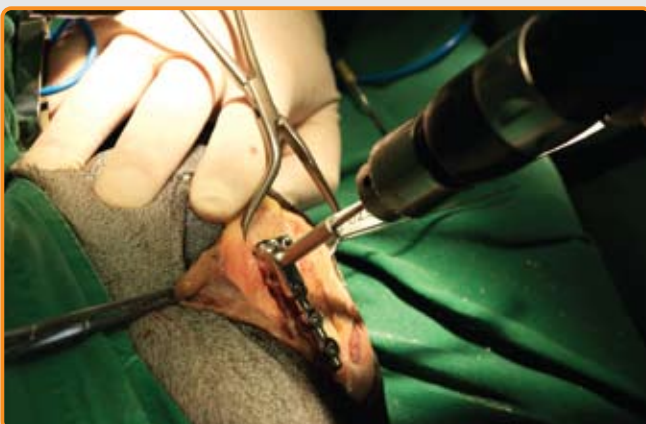



- 18** Pointed reduction forceps are placed to maintain secure, accurate reduction and apply compression across the osteotomy.
- 19** A plate is placed on the medial aspect of the tibia.

**Correct placement and alignment of the plate is essential**

- the laser marked dot should lie directly over the osteotomy
- the plate should lie as flat as possible on the bone
- the plate should lie far enough cranially to allow the caudal screw to engage the caudo-medial corner of the proximal tibia.
- the distal part of the plate should align almost to the long axis of the tibia and lie close to the caudal edge of the bone
- it is very occasionally necessary (for example, in small dogs) to bend the plate between holes 5 and 6 distally. Apart from this, the plate should not be contoured or otherwise modified.

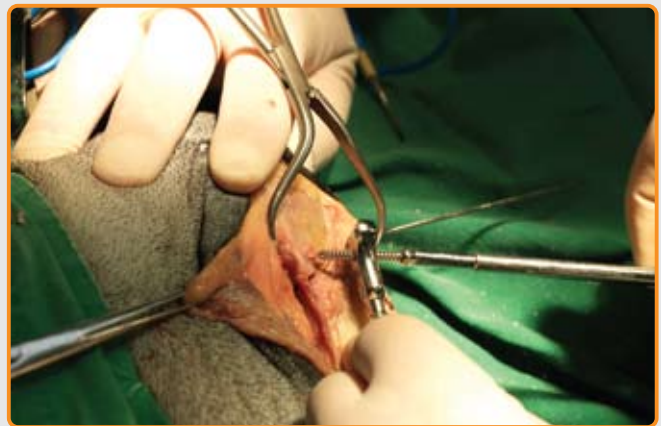
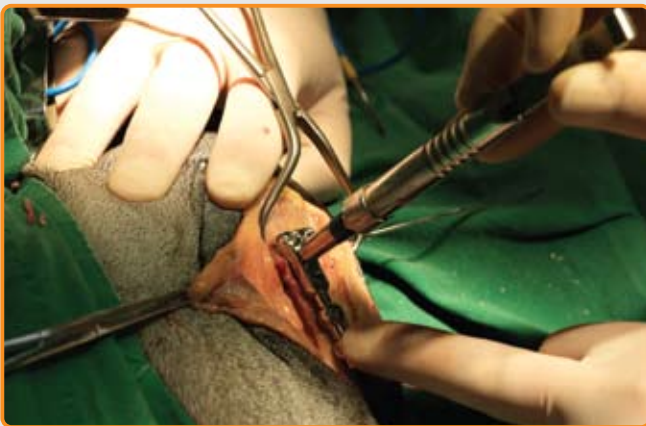

- 20** Confirming that correct plate placement and alignment has been maintained, the first hole is drilled. Make sure that the correct SOP drill guide is selected and that the guide is fully and firmly engaged in the plate before drilling.

# SOP TPLO User Guide

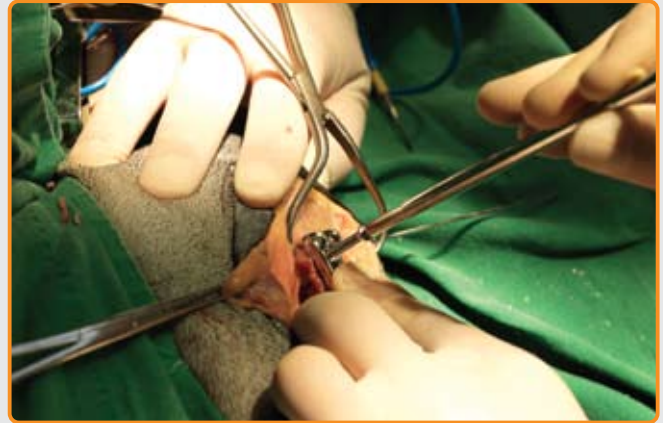
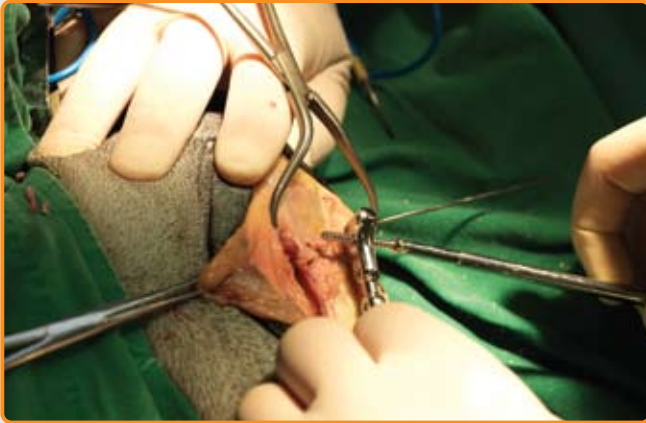
## Correct order of screw placement is essential

- screw order: 3, 1, 2, 5, 4, 6
- drill and place screws one at a time

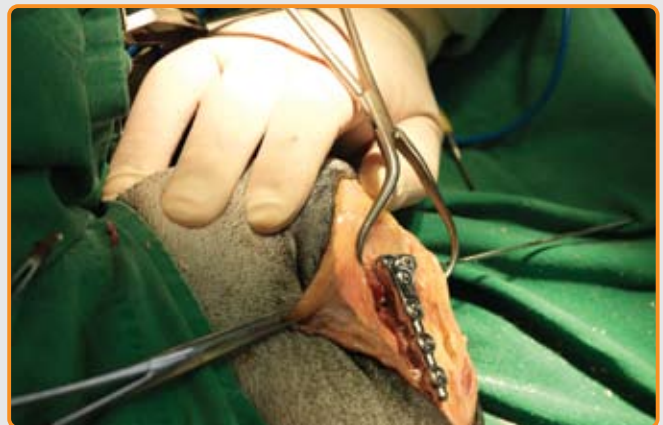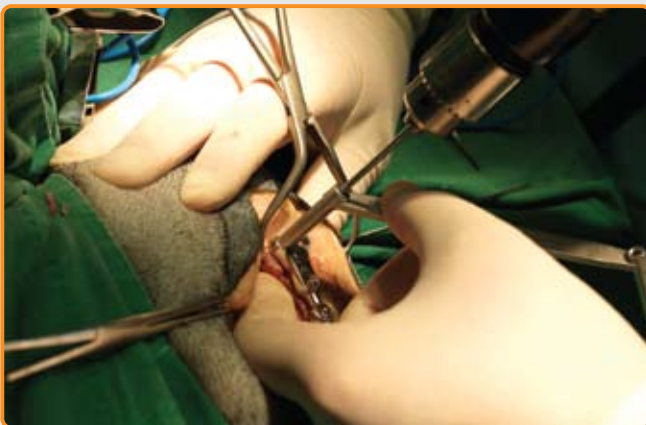


**21** Measure and select an appropriate screw. Mono-cortical screws are acceptable with locking plates and the surgeon may, on occasion choose to use shorter monocortical screws, especially for holes 5 and 6 in smaller dogs. However, the more proximal screws, especially 1, 2 and 3 engage relatively soft, cancellous bone so it is advisable to place the longest possible screw thereby engaging as much bone as possible.

**22** The first screw is advanced well through hole 3.

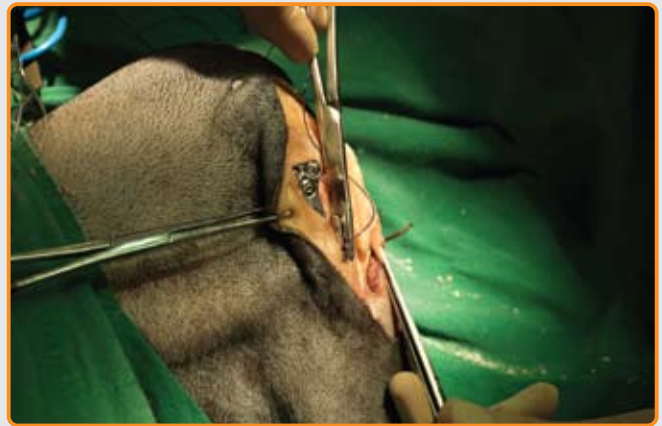
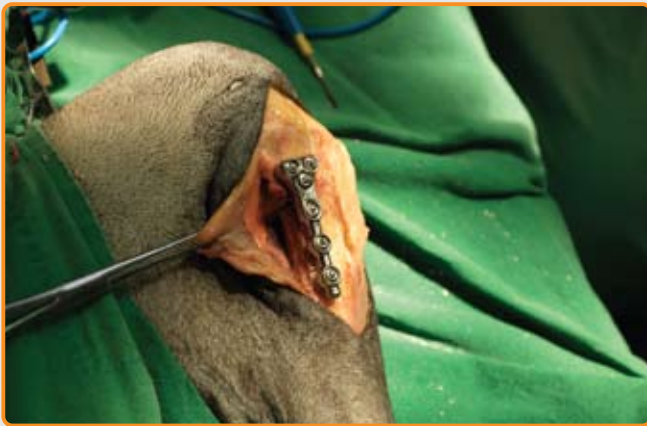
- 23** The protruding end of the screw is “offered up” to the previously drilled hole and firm pressure is maintained while the screw is carefully turned COUNTER-CLOCKWISE.
- 24** This will allow the plate to move slowly down onto the bone – as soon as the plate comes to lie against the bone, the screw is driven CLOCKWISE into the pre-drilled hole.

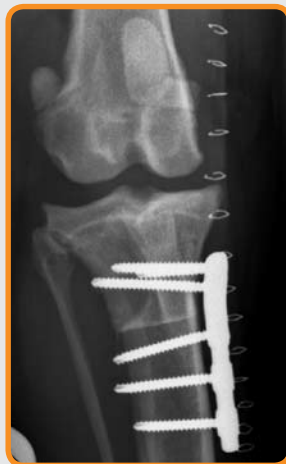
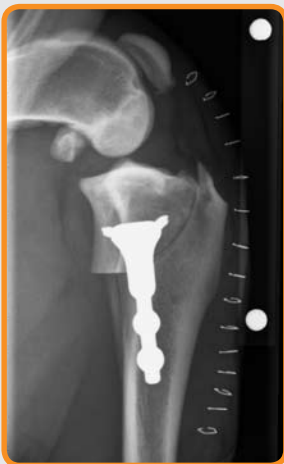
- 25** Using the SOP drill guide and employing standard technique, subsequent holes are drilled, measured and screws placed, one at a time observing correct sequence.
- 26** All six screws have been placed – the plate is now fully secure.

# SOP TPLO User Guide



- 27 The remaining arthrodesis wire and pointed reduction forceps have been removed prior to a routine wound closure.
- 28 Although the plate is relatively thick, the narrow profile and relatively short length allows easy closure of soft tissues.



- 29 Lateral and caudo-cranial radiographs showing correct placement of the SOP-TPLO plate.









**Patents Pending:**

GB0610630.6  
GB0709693.6  
PCT/B2007/001912  
EP07732933.2  
HK09106733

CN200780027302.6  
ZA2008/10100  
5213/KOLN/2008  
12/302586

**Address:**

Orthomed (UK) LTD  
70, Plover Road  
Wellington Mills  
Lindley  
Huddersfield  
West Yorkshire HD3 3HR

**Telephone:**

Tel: +44 (0) 845 045 0259  
Fax: +44 (0) 845 603 2456

**Email:**

[info@orthomed.co.uk](mailto:info@orthomed.co.uk)

**Address:**

Orthomed North America Inc.  
927 Azalea Lane  
Suite A  
Vero Beach  
Florida  
32963

**Telephone:**

Tel: +1 772-492-0111  
Fax: +1 772-492-0444

**Email:**

[mike@orthomed.co.uk](mailto:mike@orthomed.co.uk)

**Address:**

Orthomed Technology GmbH  
Am Schaafredder 17  
24568 Kaltenkirchen  
Germany

**Telephone:**

Tel: +49 (0) 4191 8030013  
Fax: +49 (0) 4191 8030014

**Email:**

[info@orthomedeu.com](mailto:info@orthomedeu.com)

[www.orthomed.co.uk](http://www.orthomed.co.uk)